



Prevalence of intestinal helminthes in feral cats in Babylon province/ Iraq, urban and rural locations

Hayder M. Al-Rammahi¹ *; Safaa M. Kareem¹ ; Ali K. Hammadi¹

¹College of Vet. Medicine /Al-Qassim Green University /Babylon –Iraq.

ARTICLE INFO

Received: 25.06.2014

Revised: 22. 07.2014

Accepted: 25.09.2014

Publish online: 15. 10.2014

***Corresponding author:**

Email address:

dr.ram69hm@yahoo.com

Abstract

This study carried on fifty seven feral cats in Babylon province urban and rural locations. The cats euthanized and examined for gastrointestinal helminthes

(GI). The results revealed that all examined cats were infected by one or more GI helminthes, which were including *Toxocara cati*, *Toxascaris leonina*, *Ancylostoma tubaeforme*, *Pterygodermatites cahirensis*, *Dipylidium caninum*, *Dipylidium nöllei*, *Taenia taeniaeformis* and *Joyeuxiella pasqualei*. The highest prevalence nematode occurred in urban habitant cats was *Toxocara cati* (43.75%) and the lowest was *Pterygodermatites cahirensis* (12.5%). However, in rural habitant cat, the highest prevalence rate of nematode was *Physaloptera praeputialis* and *Toxocara cati* (24%) followed by *Ancylostoma tubaeforme* (16%) and *Pterygodermatites cahirensis* (4 %). Among cestodes helminthes, the most prevalence species in urban habitant cat was *Taenia taeniaeformis* (31.25%) followed by *Diplopylidium nöllei* (25%), *Dipylidium caninum* (21.88%) and *Joyeuxiella pasqualei* (12.5 %). In rural habitant cats, the most prevalent cestode was *Diplopylidium nöllei* (52%), followed by *Diplopylidium caninum* (36%), *Taenia taeniaeformis* (32%) and *Joyeuxiella pasqualei* (20%).

To cite this article: Al-Rammahi Hayder M, Kareem Safaa M, Hammadi Ali K. (2014). Prevalence of intestinal helminthes in feral cats in Babylon province/ Iraq, urban and rural locations. MRVSA. 3 (2), 44-51.

DOI: [10.22428/mrvsa.2307-8073.2014.00326.x](https://doi.org/10.22428/mrvsa.2307-8073.2014.00326.x)

Keywords: Feral cat, gastrointestinal helminthes, rural and urban location, Babylon.

Introduction

In late years, the concerns about dangers of feral cats on public health have increased considerably. The cats play a role of potential reservoir for many pathogens of medical and veterinary importance (Mc Glade *et al.*, 2003). Feral cats are known as a host of many parasite species that have the ability to infect man (particularly children) and other domestic animals (Fisher, 2003). In developing countries (including Iraq), the feral cat lives freely in urban and rural areas and tend to shed helminth egg, larvae and protozoan cysts into the environment (Al-khushali, 2007). *Toxocara cati* is a common gastrointestinal nematode in cats worldwide. It is not only infecting young kittens, but can also cause human toxocariasis. These worms are mostly prevalent throughout tropical, subtropical and temperate regions (Overgaauw,

1997). Many studies were done in various countries to assess the parasite burden of feral and stray cats, such as in Thailand (Jittapalapong *et al.*, 2007), Iran (Bahadori *et al.*, 2004), Spain (Calvete *et al.*, 1998), Brazil (Labarthe *et al.*, 2004), Qatar (Abu-Madi *et al.*, 2010), England (Nichol *et al.*, 1988) and South Africa (Baker *et al.*, 1988). All these studies demonstrated that the parasites burden in feral cat was vary according to geographical regions, seasons of the year, environmental and density of feral cat population. In Iraq, there are only few studies regarding the gastrointestinal helminthes in feral cats. The present study intended to evaluate the prevalence of gastrointestinal helminthes in feral cat, in Babylon province rural and urban locations and focus on the effect of recovered parasites at the infected parts of the GIT.

Materials and methods

The study was carried during February –June 2011. Fifty seven adult feral cats (25 male and 32 female) were captured from different locations in the Babylon province by bait cage trap. The locations were grouped according to the population density into rural and urban locations. Each cat was euthanized humanely after I/M administration of 3ml ketamine and 2ml xylazine. The gastrointestinal tract was removed and separated from the mesentery, after opening of the abdominal cavity. The intestine was opened longitudinally and examined for the presence of helminthes in its content. Intestinal scrapings were also made. Helminthes species were collected and counted. Then, the parasites were relaxed in the water and fixed in a mixture of 70% ethanol and 5% glycerin. The nematodes were mounted and cleared with lactophenol according to the method described by Ash and Orihe, (1987), while the tapeworms were stained with modified carmine (Cox, 1999). All parasites were identified according to (Soulsby, 1986). The Mean intensity (MI) of infection was also calculated. According to Poulin, 1993 MI is the arithmetic mean of the number of individuals of a particular parasite species per infected host. Specimens from the infected intestine were obtained and preserved in 10% buffered formalin. After fixation tissues were processed routinely for paraffin embedding and 4-6 µm thick sections were cut and stained with hematoxylin and eosin. This research was approved according to Al-Qassim Green University guidelines for use the animals in scientific researches.

Results

All examined cats were infected with one or more GI helminthes. In this study, 5 species of nematodes and 4 species of cestodes were recorded. The recorded helminthes were *Toxocara cati*, *Toxascaris leonine*, *Ancylostoma tubaeforme*, *Pterygodermatites cahirensis*, *Dipylidium caninum*, *Diplopylidium nölleri*, *Taenia taeniaeformis* and *Joyeuxiella pasqualei*. The percentages of cestodes, nematodes and mixed infection in cats collected from rural habitant were 36 %, 8% and 56%, respectively, while in urban habitant area were 9.37 %, 31.25% and 59.37% respectively (Figure 1). According to gender, the infection rate of cestodes, nematodes and both parasite were 22.22%, 14.81% and 62.96%, respectively in male. However, the rate was 20%, 26.22% and 53.33% respectively in female.

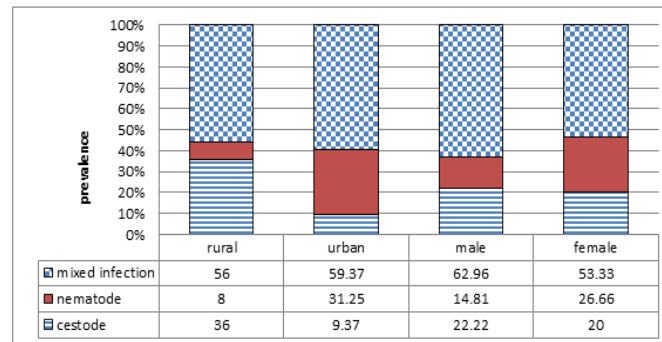


Figure (1) revealed infection in urban and, rural cats with cestodes, nematodes or both parasites

In urban habitant cats, the prevalence of nematodes revealed that *Toxocara cati* was the highest prevalence (43.75%) while, *Pterygodermatites cahirensis* (12.5%) was the lowest. However, in rural habitant cat the highest nematode was also *Toxocara cati* (24%) followed by *Ancylostoma tubaeforme* (16%) and *Pterygodermatites coherencies* 4 % with no recording to *Toxascaris leonina* (Table 1).

Table (1) revealed the prevalence and intensity of nematode species in urban and rural habitant cat

Nematodes	Urban			Rural		
	Prevalence	Intensity	Range	Prevalence	Intensity	range
<i>Toxocara cati</i>	43.75	1.76	1-3	24	1.84	1-3
<i>Toxascaris leonina</i>	21.88	1.28	1-2	0	0	0
<i>Ancylostoma tubaeforme</i>	28.13	7.66	1-15	16	8.5	5-12
<i>Pterygodermatites cahirensis</i>	12.5	1.25	1-2	4	1.5	1-2

The most prevalent species among cestodes helminthes, in urban habitant cats was *Taenia taeniaeformis* (31.25%) followed by *Diplopylidium nölleri* 25%, *Dipylidium caninum* 21.88% and *Joyeuxiella pasqualei* 12.5%. While, in rural habitant cats the most prevalent cestode was *Diplopylidium nölleri* (52%), followed by *Diplopylidium caninum* 36%, *Taenia taeniaeformis* 32% and *Joyeuxiella pasqualei* (20%) (Table 2).

Table (1) revealed the prevalence and intensity of cestodes species in urban and rural habitant cat

Cestodes	Urban		Rural	
	prevalence	intensity	prevalence	intensity
<i>Dipylidium caninum</i>	21.88	14.15	36	54.33
<i>Diplopylidium nöllei</i>	25	10.38	52	16.54
<i>Taenia taeniaeformis</i>	31.25	1.6	32	1.6
<i>Joyeuxiella pasqualei</i>	12.5	12.5	20	1.2

The number of recorded species per each animal was one parasites /animal in urban cats, while, the two parasites /animal was the most prevalent in rural cat (Table 3).

Table (2) revealed the number of recovered parasite species per animal

Habitant	number of species per animal				
	One	Two	Three	Four	More
Rural	5	13	6	0	1
Urban	12	8	7	4	1
Total	17	21	13	4	2

The histopathological changes in the infected small intestine revealed increase in numbers of goblet cells, villous atrophy and sloughing of villi at site of attachment of the cestodes (Figures 2-4).

Discussion

The results of the present study revealed high prevalence of intestinal helminthes in feral cat in the Babylon province, in comparison with other studies which were done in different places of Iraq (Al-khushali, 2007; Daoud, 1988), and other countries (Abu-Madi, 2010; Nichol, 1988; Okaeme, 1986). The reasons for high prevalence might be related to poor hygienic conditions, abundance of intermediate hosts and increase the feral cat's population density. The increase in the prevalence of cestodes in rural areas and nematodes in urban areas might be explained by pattern of life cycles, as most cestodes need intermediate hosts, which has been distributed in rural environment and vice versa in case of nematodes (Bowman, 2002, Al-Khalidi *et al.*, 1988).

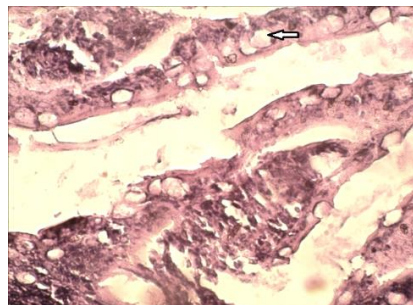


Figure 2: revealed increase goblet cells in mucosa of small intestine infected with GIT helminthes (H &E stain, 40X).

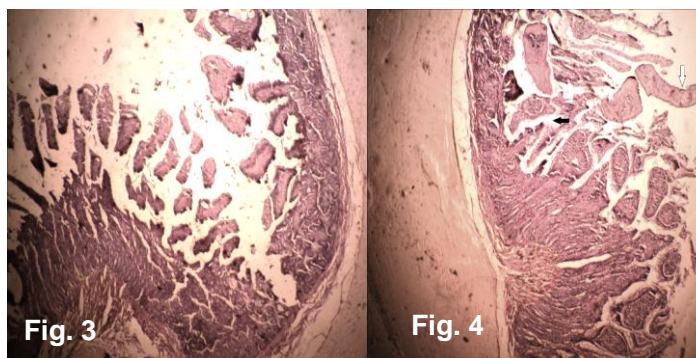
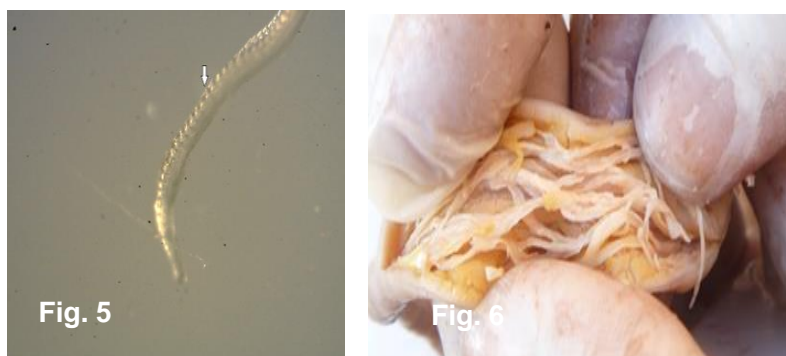

Figure 3: Revealed obvious sloughing of small intestine mucosa infected with GIT helimenthes (H &E stain, 10X)

Figure 4: revealed villi atrophy (black arrow) with segments of tape worm) (white arrow) (H &E stain, 10X)

In this study, the prevalence of *Toxocara cati* was similar to the previous studies performed on feral cats in Iraqi and other countries (Okaeme, 1986, Bahadori *et al.*, 2002, Jamshidi, 2002). The Transmission of *Ancylostoma spp.* depends on the number of infected dogs that eliminate the eggs in their feces. The fecal samples being left on moist ground for 2-8 days and upon a susceptible host either ingesting larvae or being actively infected through the skin. In previous studies, the estimated prevalence were 30% in Mosul (Al-Khalidi *et al.*, 1988) and 39.6% in Baghdad (Al-khushali, 2007) .The present study was considered as a second study that report the incidence of *Pterygodermatites cahirensis* (Figure 5), where the first incidence was reported by Daoud, (1988), in Iraqi cat in Baghdad.

The prevalence and intensity of *Diplopylidium spp.* (Figure. 6) in this study revealed the highest percentage in rural area. The reasons might be related to the mode of the transmission the parasites which depends on coprophagus beetles, which serve as a second intermediate hosts.



The prevalence of *Diplopylidium spp.* , in this study is compatible with previous studies . It was 24% in Mosul (Al-Khalidi *et al.*, 1988) and 30.9% in Baghdad (khushali, 2007), 47% in Qatar (Abu-Madi, 2010) and 54% in northern Iran (Changizi *et al.*, 2007). The prevalence of *Taenia taeniaeformis* (Figure7) in the present study was 30.25% and 32% in rural and urban areas respectively, these results were higher than studies have been previously reported in Iraq (Bahadori *et al.*, 2004, Al-khushali, 2007).

In conclusion, the stray cats serves as potential reservoir host for a variety of parasites, which might be played important role for human and animal health. The massive distribution of stray cats in most Iraqi cities need more attention by related authorities particularly public health and veterinary service to limit their hazards and zoonotic problems.

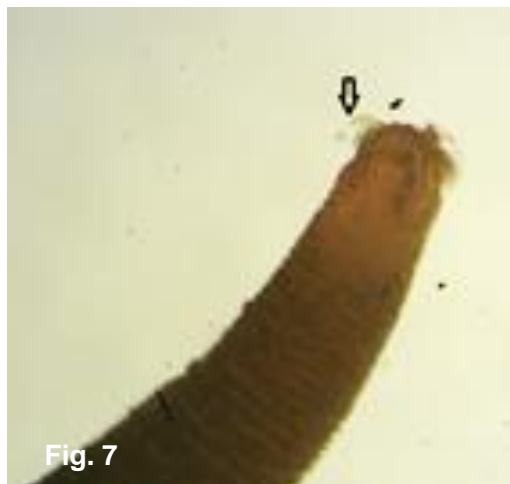

Figure (7) Reveals *Taenia taeniaeformis* with characteristic thorn like hooks

References

- Abu-Madi M A, Behnke J M, Prabhaker KS, Al-Ibrahim R J and Lewis W. (2010).** Intestinal helminths of feral cat populations from urban and suburban districts of Qatar. *Veterinary Parasitology*. 168: 284–292.
- Al-Khalidi N W, Al-Alousi T and Subber A. (1988).** Internal and external parasites in cats in Mosul, Iraq. *Veterinary Parasitology*. 2,137-138.
- Al-khushali M N. (2007).** Prevalence of Zoonotic Parasites in Stray Cats in Baghdad. *The Iraqi postgraduate medical journal*. 6 (2):152-156.
- Ash L R and Orihel T C. (1987).** *Parasites: A guide to laboratory procedures and identification* .ASCP Press, American Society Pathologists Chicago.
- Bahadori Sh R, Eslami A, Meshgi B and Poor Hoseini S. (2004).** Study on stray cats infested with parasitic helminthes in Tehran, Iran. *J Fac Vet Med Univ Tehran*. 59 (2):171-174.
- Baker M K, Lange L, Verster A and Van Der Plaat S A. (1988).** Survey of helminths in domestic cats in the Pretoria area of Transvaal, Republic of South Africa: I. The prevalence and comparison of burdens of Helminthes in adult and juvenile cats. *J. S. Afr. Vet .Assoc*. 60:139-42.
- Bowman D D, Hendrix C M, Lindsay D S and Barr S C. (2002).** *Feline clinical parasitology*, A Blackwell Science Company. Iowa State University Press.

Calvete C, Lucientes J, Castillo J A, Estrada R, Garcia M J, Peribanez M A. and M Ferrer. (1998). Gastrointestinal helminth parasites in stray cats from the mid-Ebro Valley, Spain. *Veterinary Parasitology*. 75: 235-240.

Changizi E, Mobedi I, Salimi-Bejestani M R and Rezaei-Doust A.(2007).Gastrointestinal helminthic parasites in stray cats (*Felis catus*) from north of Iran. *Iranian Journal of Parasitology*. 2: 25–29.

Cox F E G. (1999). Modern parasitology: A text book of parasitology, 2nd ed., Blackwell publishing, Oxford .75-114.

Daoud I S, Al Tae A R A and Salman Y J. (1988). Prevalence of gastro-intestinal helminthes in cats from Iraq. *J Biol Sci Res*. 19:363–368.

Fisher M. (2003). *Toxocara cati*: an underestimated zoonotic agent. *Trends parasitology*. 19:167-170.

Georgi J R. (1987). Tapeworms. *Vet Clin North Am: Small Anim Pract*. 17:1285-1305

Jamshidi Sh, Meshki B and Toghani M. (2002). A study of helminthic infection of gastrointestinal tract in stray cats at urban areas in Isfahan, Iran. *J Fac Vet Med Univ Tehran*. 57(2):25-27.

Jittapalapong S, Inparnkaew T, Pinyopanuwat N, Kengradomkij C, Sangvaranond A and Wongnakphet S. (2007). Gastrointestinal Parasites of Stray Cats in Bangkok Metropolitan Areas, Thailand. *Kasetsart J. (Nat. Sci.)*. 41: 69 - 73.

Labarthe N, Serrao M L, Ferreira A M R, Almeida N K O and Guerrero J. (2004). A survey of gastrointestinal helminthes in cats of the metropolitan region of Rio de Janeiro, Brazil. *Veterinary Parasitology*. 123(1-2): 133-139.

Mc Glade T R, Robertson I D, Elliot A D, Read C and Thompson R C A. (2003).Gastrointestinal parasites of domestic cats in Perth, Western Australia. *Veterinary Parasitology*. 117(4): 251-262.

Nichol S, Ball S J, Snow K R. (1988). Prevalence of intestinal parasites in feral cats in some urban areas of England. *Veterinary Parasitology*. 9:107-110.

Okaeme A N. (1986). Intestinal helminthes of cats in the Kainji Lake area, Nigeria. *Veterinary Research Communications*.10 (3): 237-40.

Overgaauw P A M. (1997). Aspects of *Toxocara* epidemiology: toxocarosis in dogs and cats. *Critical Reviews in Microbiology*. 23: 233–251.

Soulsby E J L. (1986). Helminthes, Arthropods and Protozoa of Domesticated Animals. Baillier Tindal London.7th ed. Baillier Tindall publishers, Philadelphia, London, Toronto.175-390.

Woon–Mork SOHN & Jang-Yil CHAI. (2005).Infection status with helminthes in feral cats purchased from a market in Busan, Republic of Korea. The Korean Journal Parasitology. 43(3): 93-100.